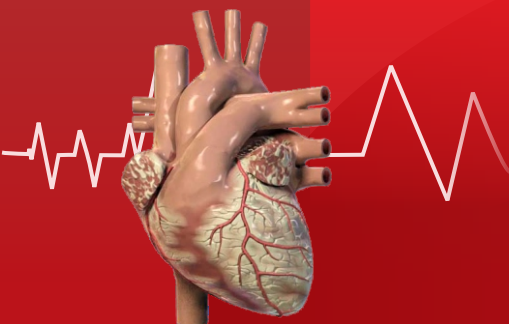

Healthy Heart

Volume-4 | Issue-38 | January 5, 2013

Price : ₹ 5/-

Honorary Editor :

Dr. Dhiren Shah



From the desk of Editor:

Approximately 50% to 60% of patients with congestive heart failure have some degree of mitral regurgitation (MR), and in 30% of these, the MR is moderate or severe. The majority of these individuals have a structurally normal mitral valve (MV), but the valve is incompetent because of left ventricular remodeling that has disturbed the relationship between the subvalvular apparatus and the MV leaflets. This type of MR is referred to as functional MR. Functional MR in the subgroup of patients in which the underlying ventricular remodeling is due to a myocardial infarction (MI), is referred to as ischemic MR. The presence of MR after an MI is associated with a worse prognosis. In those with 3+ to 4+ MR, the 5-year survival is approximately 50%, even with surgical intervention. Coronary revascularization does little to improve the severity of the regurgitation. Although MR can be resolved acutely with mitral valve repair, there is a high rate of recurrence. Newer surgical techniques are focusing on the subvalvular apparatus in an attempt to achieve better results. The data with these techniques are limited, and the long-term results are not known. The constraint devices, along with the percutaneous approaches, show promise, but more data are needed before their widespread use.

- Dr. Dhiren Shah

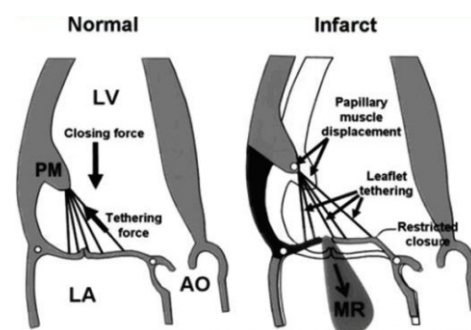
Surgical Options of Ischemic Mitral Regurgitation

Definition, Classification and Pathophysiology of Chronic Ischemic Mitral Regurgitation

Ischemic MR is defined as MR complicating the manifestations of coronary artery disease in the absence of primary leaflet, or chordal pathology. Any disruption of the proper function of the mitral annulus, the valve leaflets, the chordate tendineae, the papillary muscles, or the supporting left ventricular walls may lead to MR.

The cause of MR in ischemic MR is due to (1) mitral annular dilatation, and/or (2) papillary muscle displacement. This process causes (1) leaflet malcoaptation, which is the failure of the leaflets to meet, and (2) malapposition, which is the failure of the leaflets to close at the same plane. Although mitral annular dilatation has been described as a cause of MR, it has been shown that isolated annular dilatation, per se, does not cause significant regurgitation. In only 5% of the cases of ischemic MR does annular dilatation play a significant role. This means that the predominant cause of ischemic MR is the apical and lateral displacement of the papillary muscles,

leading to tethering of the MV leaflets, with subsequent decreased coaptation. This tethering of the leaflets is more commonly seen after a posteroinferior than an anterolateral wall MI. Therefore, it is more common for the posteromedial papillary muscle to be the culprit associated with ischemic MR.



Coronary Artery Revascularization

Since the underlying cause of ischemic MR is coronary artery disease, it would seem intuitive that coronary artery revascularization would ameliorate the severity of the MR. However, the data shows that in most patients coronary artery revascularization does not correct the MR. A study of 136 patients with ischemic MR who underwent isolated coronary artery bypass graft surgery (CABG) showed on postoperative transthoracic echocardiogram that 40%

Cardiologists

Dr. Anish Chandarana (M) +91-98250 96922 Dr. Keyur Parikh (M) +91-98250 26999

Dr. Ajay Naik (M) +91-98250 82666 Dr. Milan Chag (M) +91-98240 22107

Dr. Satya Gupta (M) +91-99250 45780 Dr. Urmil Shah (M) +91-98250 66939

Dr. Gunvant Patel (M) +91-98240 61266 Dr. Hemang Baxi (M) +91-98250 30111

Pediatric Cardiologists

Dr. Kashyap Sheth (M) +91-99246 12288 Dr. Milan Chag (M) +91-98240 22107

Cardiothoracic & Vascular Surgeons

Dr. Dhiren Shah (M) +91-98255 75933

Dr. Dhaval Naik (M) +91-90991 11133

Dr. Dipesh Shah (M) +91-90990 27945

Pediatric & Structural Heart Surgeons

Dr. Shaunak Shah (M) +91-98250 44502

Dr. Ashutosh Singh (M) +91-82380 01976

Vascular & Endovascular Surgeon

Dr. Srujal Shah (M) +91-91377 88088

Cardiac Anaesthetists

Dr. Niren Bhavsar (M) +91-98795 71917

Dr. Hiren Dholakia (M) +91-95863 75818

Dr. Chintan Sheth (M) +91-91732 04454

Neonatologist and Pediatric Intensivist

Dr. Amit Chitaliya (M) +91-90999 87400

Cardiac Electrophysiologist

Dr. Ajay Naik (M) +91-98250 82666

of patient were left with 3 to 4 + MR, and 51% were left with 2+ MR. Only 9% of patients had significant improvement, with no more than trace (0 to 1 +) MR. Another report of 92 patients with 3+ to 4+ ischemic MR undergoing isolated CABG showed that in postoperative echocardiographic follow – up, nearly half the patients still had 3+ to 4 + MR.

CABG versus CABG And MV Repair

To date, no randomized trial has been conducted to evaluate the efficacy of MV repair when performed at the time of CABG. The published data have all been retrospective analyses. Wu et al evaluated 682 patients with moderate to severe MR and ejection fraction < 30% who underwent CABG ; 419 patients underwent CABG alone, and 126 underwent CABG with MV repair . When the CABG MV repair group was compared with the CABG group, there was no demonstrable mortality benefit conferred by the MV repair. Another study from the Cleveland Clinic evaluated 390 patients with 3+ / 4 + MR, with varying degrees of left ventricular systolic dysfunction . Of these, 290 patients underwent CABG with MV repair and were compared with 100 patients who underwent CABG alone. Their conclusions were that the addition of MV annuloplasty to CABG did not improve long – term functional status or survival. Similar studies have come to the same conclusions.

Mitral Valve Replacements

Although no randomized trial has been performed comparing the benefits of MV replacement versus MV repair, it appears that MV repair has a lower operative mortality and a better long – term survival when compared with MV replacement. However, MV replacement is still a reasonable option for patients with acute MR, and for those with chronic ischemic MR and multiple comorbidities, complex regurgitant jets (noncentral jet or more than one jet), or severe tethering of both MV leaflets. When considering which type of valve to implant, it is important to take into account that the majority of patients do not survive much longer than 5 years. A bioprosthetic valve in the mitral position starts to deteriorate approximately 6 years postimplant. As a result, some surgeons recommend the use of a bioprosthetic valve over a mechanical one, irrespective of the patient's age, to avoid chronic anticoagulation. Also, chordal preservation is less technically demanding, and there are fewer potential postoperative valve-related complications if a bioprosthetic valve is used.

To evaluate the safety and efficacy of MV repair and MV replacement for patients with severe ischemic MR, a multicenter randomized trial titled “ Evaluation of Outcomes Following Mitral Valve Repair/ Replacement in Severe Chronic Ischemic Mitral Regurgitation is now taking place.

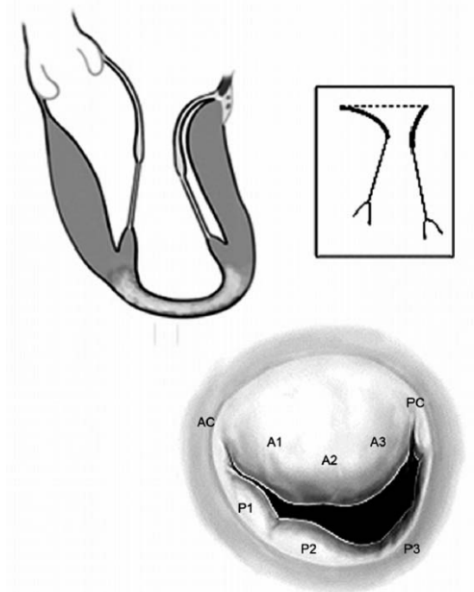


Figure-2 : Restricted leaflet motion. It is noticed in the cross sectional view of the mitral valve that segments P3/P2 do not coapt due to restricted motion of the leaflet. Type IIIb dysfunction of Carpentier's classification.

Patients will be randomized to MV repair with annuloplasty and a subvalvular procedure for severe tethering, or to MV replacement with complete preservation of the subvalvular apparatus. The primary end point of the study is the degree of left ventricular remodeling at 12 months .

Mitral Valve Repair

The most common type of surgery performed for ischemic MR is an undersized mitral annuloplasty. In this technique, a small (size 24 to 26 mm) mitral annuloplasty ring is used which causes a reduction in the anteroposterior (septolateral) diameter of the MV increasing the surface of coaptation. The procedure is fairly easy to perform and reproducible. Over the

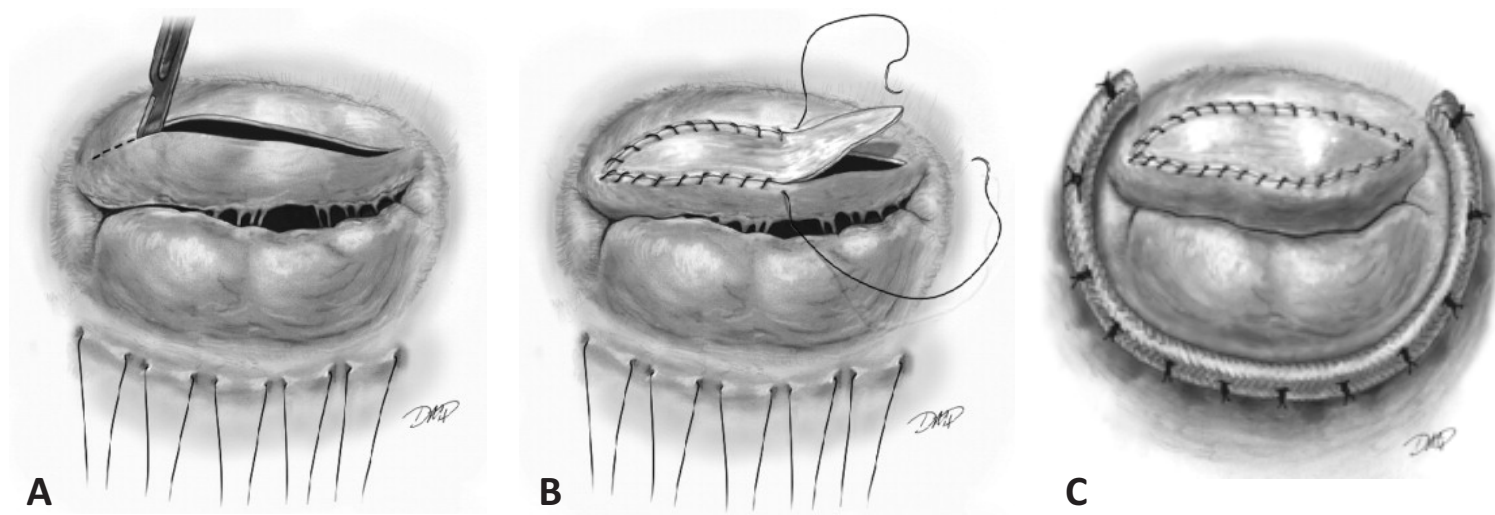


Figure-3 : Anterior leaflet augmentation. A, the mitral valve as viewed from the surgeon's perspective with sutures in the posterior annulus. An incision is made in the anterior leaflet from commissure to commissure, with a resultant elliptical defect. B, Anterior leaflet augmented with bovine pericardium. C, Completed repair with partial, flexible annuloplasty ring.

past few years, many different types of prosthetic rings have been developed, some are flexible, others rigid, some are complete, others incomplete. However, there are no definite data that show that one ring is superior to another.

Surgical Ventricular Restoration with Papillary Muscle Imbrication

The term "Surgical Ventricular Restoration" includes operative methods that reduce left ventricular volume and restore the ventricular

elliptical shape. Its use is limited to anterior wall MIs. In this technique, the anteroapical, apical, and anterolateral left ventricular scarred segments are excluded from the rest of left ventricle with an intracardiac patch or by direct closure. By altering the shape of the left ventricle and reducing wall stress, this procedure can reduce papillary muscle displacement and subsequent MR.

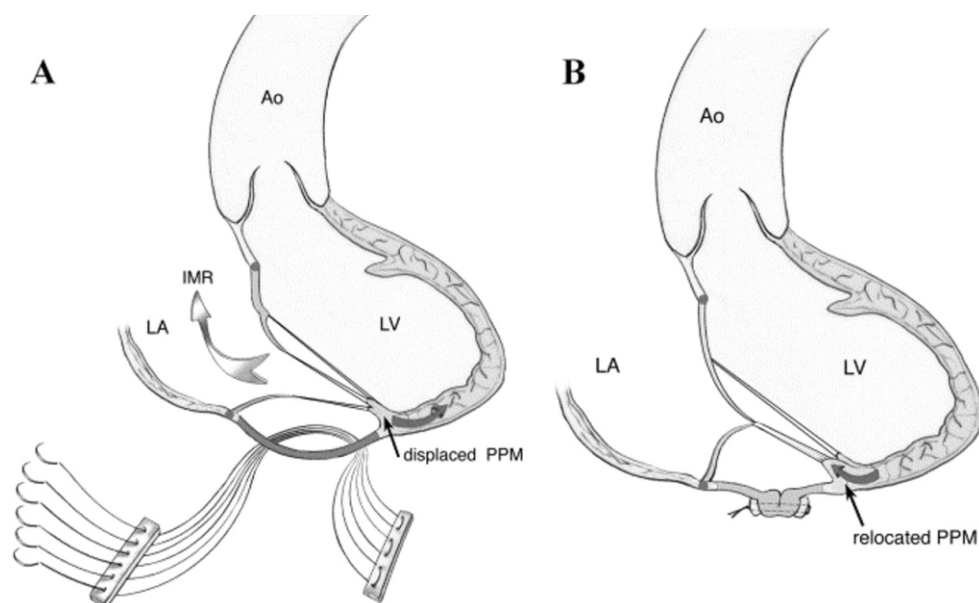


Figure : Infarct Plication. A, schematic representation of the akinetic inferobasal segment with tethering of the posterior leaflet. The sutures are shown before tightening. B, Plication of the dyskinetic segment with relocation of the posterior papillary muscle. LA indicates Left atrium; LV, left ventricle; Ao, aorta; IMR, ischemic mitral regurgitation; PPM, posterior papillary muscle.

External Compression Devices

An innovative strategy to remodeling has been the development of constraint devices. These devices are intended to improve left ventricular function by reducing wall stress, and provide passive diastolic support. The Acorn Corcap cardiac support device is a biocompatible mesh – like jacket that slips around the heart during surgery. It was evaluated in the ACORN trial, which was an unblinded trial that randomized 300 patients to 2 treatment arms depending on a need for MV surgery or

only medical treatment, with or without use of the support device. In the subgroup of 193 patients who were enrolled in the MV repair/ replacement stratum, 102 patients were randomized to the MV surgery alone group (control), and 91 were randomized to the MV surgery with implantation of the support device. At 23 months median follow – up, the addition of the support device led to greater decreases in left ventricular volumes, a more elliptical left ventricle shape, a trend for reduction in major cardiac procedures, and improvement in quality of life compared with MV surgery alone .

Percutaneous Procedures

The percutaneous approach for the treatment of MR is in its early stages of development. One approach to reduce in the coronary sinus. The CARILLON Mitral Annuloplasty Device European

Union Study (AMADEUS) study showed that at 6 months, the device reduced MR by 23% and improved quality of life and exercise tolerance.

Another technique uses a trans – septal approach to perform an edge – to – edge mitral valve repair by placing a clip in the center of the mitral orifice. This was evaluated in the Endovascular Valve Edge-to-Edge Repair studies (EVEREST I and II). A total of 107 patients with 3+ to 4+ MR were treated. Acute procedural success was achieved in 79 of 107 (74%) patients, and 51 (64%) were discharged with MR of < 1+. Thirty – two patients, (30%) had mitral valve surgery during the 3.2 years after the clip procedure. A total of 50 of 76 (66%) successfully – treated patients were free from death, mitral valve surgery, or MR >2+ at 12 months. Kaplan – meier freedom from death was 95.9%, 94.0%,

and 90.1% and Kaplan – Meier freedom from surgery was 88.5%, 83.2%, and 76.3% at 1, 2, and 3 years, respectively. The 23 patients with functional MR had similar acute results and durability.

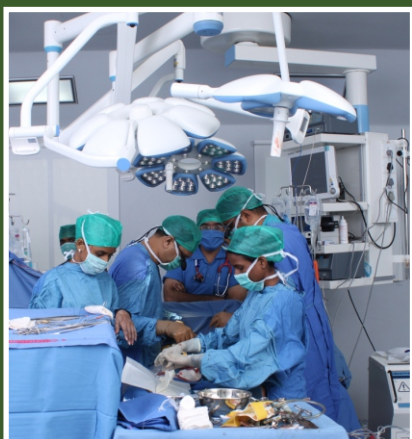Recommendations / Our Experience

The American College of Cardiology / American Heart Association state in their latest valvular heart disease guidelines that “ The best operation for ischemic MR is controversial, but MV repair with an annuloplasty ring is the procedure of choice in most instances.” At our institution, MV repair for ischemic MR usually involves implanting a complete rigid saddle – shaped ring and dog bone shaped (GeoForm ring), sized to the intertrigonal space and anterior leaflet. In patients who do not need coronary revascularization, we perform all the MV repairs via a minimally invasive approach, regardless of the left ventricular function.



CIMS Cardiac Surgery

One of the most reputed cardiac surgical care team of India

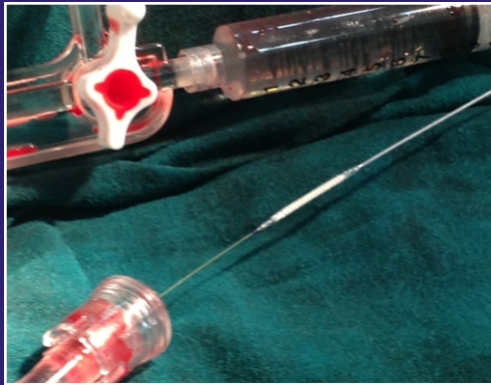
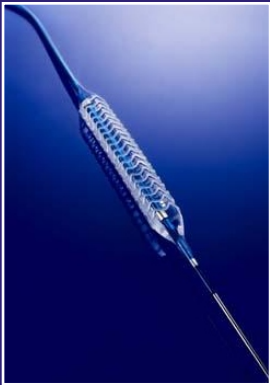
- ◆ Congenital heart surgery
- ◆ Minimal Invasive Cardiac Surgery (MICS)
- ◆ Mitral valve repair
- ◆ Single, double and multiple valve replacement / repair
- ◆ Aortic root replacement
- ◆ Off Pump CABG on beating heart
- ◆ CABG with SVR (Surgical Ventricular Restoration) for CAD, LV dysfunction, CHF
- ◆ PDA, ASD, VSD, TOF etc
- ◆ Combined carotid and by pass procedure



International patient fitted with the world's first drug eluting Bioresorbable Vascular Scaffold

One of the first cases of India



CIMS launches
its Multi-Absorbable First time
in Gujarat/India
with one of the first
"triple and double" BVS
(Reabsorbable Stents)
placed on the same day in
India in 2 patients to avoid
Bypass surgery

This new variety of dissolvable stent, Absorb is the latest innovation in the healthcare industry

- Revolutionary Technology allows blood vessels to return to natural state without blocks
- Treated Vessel resume natural function and movement as devoid of any metallic input
- Reduction in use of anti-clotting medications



CIMS Pediatric Cardiac Surgery

One of the most reputed pediatric cardiac care team of India



- ◆ Exclusive staff (surgeon, anaesthetist, perfusionist, intensivists) for complete neonatal & pediatric surgery
- ◆ State-of-the-art post operative cardiac ICU
- ◆ Availability of advanced techniques and therapeutics for life support

CIMS HTN (Hypertension) Clinic

High blood pressure is a common condition in which the force of the blood against your artery walls is high enough that it may eventually cause health problems, such as heart disease, stroke, kidney failure & blindness.



New exciting therapy

High blood pressure patients taking 3 or more medicines for high blood pressure will be provided following FREE services:

Free Consultation ◆ Free Echo ◆ Free Renal Doppler

You may call any of our CIMS Cardiologists listed below

| | |
|----------------------|---------------------|
| Dr. Anish Chandarana | (M) +91-98250 96922 |
| Dr. Ajay Naik | (M) +91-98250 82666 |
| Dr. Satya Gupta | (M) +91-99250 45780 |
| Dr. Gunvant Patel | (M) +91-98240 61266 |
| Dr. Keyur Parikh | (M) +91-98250 26999 |
| Dr. Milan Chag | (M) +91-98240 22107 |
| Dr. Urmil Shah | (M) +91-98250 66939 |
| Dr. Hemang Baxi | (M) +91-98250 30111 |



CIMS Hospital

Nr. Shukan Mall, Off Science City Road, Sola,
Ahmedabad-380060. Ph.: +91-79-2771 2771-75 (5 lines)
For appointment call : +91-79-3010 1200, 3010 1008
Mobile : +91-98250 66661 or email on opd.rec@cims.me

CIMS-CON

2014

Education For Innovation

January 10-12, 2014

10th Annual Scientific Symposium
19th Year of Academics

Organized by



CIMSRE
Care Institute Medical Society
for Research and Education

Lifetime Academic Event not to be Missed

CIMS-CON is proud to announce its association with
American Association of Physicians of Indian Origin (AAPI)
for CIMS-CON 2014

Book your dates for 2014

Special Discounted Registration

₹ 2,500/- only*

(*Offer valid till March 31, 2013)

**SUPER
EARLY BIRD
REGISTRATION**

The first 1000 registered delegates will get a GIFT.

CIMS-CON 2014 Registration Form

Cheque or DD's to be made A/C payee and in the name of 'CIMS Hospital Pvt. Ltd.'

Kindly mail the registration form along with the cheque/DD to our office.

All Cash Payments are to be made at 'CIMS Hospital, Ahmedabad' only.

Please note that it is mandatory to provide all the information. Please fill in all fields in CAPITAL LETTERS

Full Name

Qualification

Resi. Address

City Pin Code

Phone (STD code) Mobile

Email

Payment Details

₹ ₹ in word :

DD/Cheque No. Date Bank :

CIMS Hospitals, Nr. Shukan Mall, Off Science City Road, Sola,
Ahmedabad-380060. Phone : +91-79-3010 1059 / 1060

Fax: +91-79-2771 2770 (M) +91-98250 66664, 98250 66668

Email : cimscon@cims.me, www.cimscon.com / www.cims.me

Signature :

Healthy Heart Registered under **RNI No. GUJENG/2008/28043**

Permitted to post at PSO, Ahmedabad-380002 on the 12th to 17th of every month under
Postal Registration No. **GAMC-1725/2012-2014** issued by SSP Ahmedabad valid upto 31st December, 2014
Licence to Post Without Prepayment No. **CPMG/GJ/97/2012** valid upto 30th June, 2014

If undelivered Please Return to :

CIMS Hospital, Nr. Shukan Mall,
Off Science City Road, Sola, Ahmedabad-380060.
Ph. : +91-79-2771 2771-75 (5 lines)
Fax: +91-79-2771 2770
Mobile : +91-98250 66664, 98250 66668

Subscribe "Healthy Heart" : Get your "Healthy Heart", the information of the latest medical updates only ₹ 60/- for one year.

To subscribe pay ₹ 60/- in cash or cheque/DD at CIMS Hospital Pvt. Ltd. Nr. Shukan Mall, Off Science City Road, Sola, Ahmedabad-380060. Phone : +91-79-3010 1059 / 3010 1060. Cheque/DD should be in the name of : **"CIMS Hospital Pvt. Ltd."**

Please provide your **complete postal address with pincode, phone, mobile and email id** along with your subscription

CARE INSTITUTE OF MEDICAL SCIENCES



A premier multi-super specialty
GREEN Hospital



 **CIMS**®
Care Institute of Medical Sciences
At CIMS... we care

CIMS Hospital : Nr. Shukan Mall, Off Science City Road, Sola, Ahmedabad-380060. Ph.:
+91-79-2771 2771-75 (5 lines) email : info@cims.me web : www.cims.me
For appointment call : +91-79-3010 1200, 3010 1008
Mobile : +91-98250 66661 or email on opd.rec@cims.me

Ambulance & Emergency : +91-98244 50000, 97234 50000, 90990 11234

Printed, Published and Edited by Dr. Keyur Parikh on behalf of the CIMS Hospital
Printed at Hari Om Printery, 15/1, Nagori Estate, Opp. E.S.I. Dispensary, Dudheshwar Road, Ahmedabad-380004.
Published from CIMS Hospital, Nr. Shukan Mall, Off Science City Road, Sola, Ahmedabad-380060.